Toxicologic Pathology, 33:35–40, 2005
Copyright © by the Society of Toxicologic Pathology
ISSN: 0192-6233 print / 1533-1601 online
DOI: 10.1080/01926230590522077

Comparative Hepatic Toxicity: Prechronic/Chronic Liver Toxicity in Rodents

JERRY F. HARDISTY AND AMY E. BRIX

Experimental Pathology Laboratories, Inc., Research Triangle Park, North Carolina 27709, USA

ABSTRACT

The morphologic assessment of the gross and microscopic appearance of the liver can provide a broad base of knowledge concerning the potential toxicity of a drug or chemical. This information may either lead to an understanding of the underlying mechanism of toxicity or guide further study to discern the mode of action of the hepatotoxicity. In standard regulatory bioassays, toxicity studies are conducted during phase 1 and phase 2 of the development process to define the acute, subchronic and chronic toxicity of the test compound. In the liver, there are a limited number of morphologic changes that can be identified using conventional light microscopy. These morphologic alterations are often characterized as "adaptive," consisting of an exaggerated normal physiologic response; "pharmacologic," consisting of an expected alteration in response to the desired action of the test article; or "adverse," consisting of morphologic alterations that are generally undesired, progressive and deleterious to the normal function of the cell(s) involved. Morphologic evidence of adverse effects may involve hepatocytes, the biliary system, hepatic vasculature, Kupffer cells, or stellate cells (Ito cells). In drug discovery and development programs, it is necessary to utilize a multidisciplinary approach, using different endpoints, to investigate the same or similar biological responses in the liver. This results in large amounts of data that must be organized in a retrievable fashion. In order for such a multidisciplinary approach to succeed, each discipline must organize and generate their data in a manner that is easily used by others in the process. The toxicologic pathologist must develop and use standardized nomenclature and diagnostic criteria when examining the liver so that data from various investigators can be compared in a useful manner.

Keywords. Liver; rodent; toxicity; imaging techniques; nomenclature; diagnostic criteria.

INTRODUCTION

In today's drug discovery and development environment, there is a concerted effort to identify potential drug-induced toxicities as early as possible without eliminating promising new treatments for disease. The approach to drug discovery has undergone a huge transformation in the past decade with the rapid growth of molecular techniques and new understandings of the human genome. The use of computational chemistry makes the potential number of drug candidates identified during discovery essentially limitless. However, methods that are used in drug development have not kept pace with drug discovery. Most of the protocols and techniques that are used in drug development have changed very little in the past 30 years. There are several new and promising areas that are rapidly advancing that may revolutionize the entire drug development process. These include toxicogenomics, proteonomics, metabolonomics, gene expression using tissue arrays and new imaging techniques. In the past, the drug development process relied principally on scientists in the fields of biology, pharmacology, chemistry, genetics, statistics, toxicology, and pathology. With the advanced technologies that are being used today, the drug development team also includes engineers, mathematicians, computer scientists and molecular biologists.

The Food and Drug Administration has recognized this large gap between drug discovery research and drug development and has recommended a multidimensional critical path that leads from discovery or design concept to commercial marketing. The goal of critical path research is to develop new scientific and technical tools, including assays, standards, computer modeling techniques, biomarkers and clinical trial endpoints. The application of these tools to the drug development process will make the process more efficient and effective with the ultimate result of safe products that benefit patients (FDA, 2004).

Utilizing a large multidisciplinary approach with different endpoints to investigate the same or similar biological responses in the liver, results in large amounts of data that must be organized in a retrievable fashion. It is necessary to develop sophisticated data mining procedures that are capable of assisting the scientists in the use of these large data sets to identify potential adverse responses in the liver. In order for such a multidisciplinary approach to succeed, each discipline must organize and generate their data in a manner that is easily used by others in the process. The toxicologic pathologist must develop and use standardized nomenclature and diagnostic criteria when examining the liver so that data from various investigators can be compared in a useful manner. Additionally, the routine use of peer review procedures by toxicologic pathologists during drug development must be encouraged to add consistency and accuracy to each data set (Ward et al., 1995).

HEPATIC RESPONSES TO INJURY

The liver is a major target organ of chemically induced toxicity. Serious drug-induced liver injury is the leading single cause for withdrawal of approved drugs from the U.S. market. It also accounts for more than 50% of the cases of liver failure in the United States today (Lee, 2003). The liver is centrally

Address correspondence to: Dr. Jerry F. Hardisty, Experimental Pathology Laboratories, Inc., P.O. Box 12766, Research Triangle Park, North Carolina 27709, USA; e-mail: jhardisty@epl-inc.com

located between the gastrointestinal tract where absorption of ingested drugs occurs and the organs that are targets of these drugs and is central to the metabolism of nearly all xenobiotics. Most drugs are lipophilic, which enables them to be absorbed by the mucosal surfaces of the intestinal mucosa. Biochemical processes in the hepatocyte metabolize many drugs, so they are more hydrophilic, resulting in metabolites that are water-soluble and can be excreted in the bile or urine.

The morphologic assessment of the gross and microscopic appearance of the liver can provide a broad base of knowledge concerning the potential toxicity of a drug or chemical. This information may lead to an understanding of the underlying mechanism of toxicity or guide further study that will assist in determining the mode of action of the hepatotoxicity. In standard regulatory bioassays, toxicity studies are conducted during phase 1 and phase 2 of the development process to define the acute, subchronic and chronic toxicity of the test compound. In acute and subchronic bioassays, a range of doses is commonly used to establish a "no-observed-effect level" (NOEL), to establish maximum tolerated doses (MTD) for chronic toxicity studies, and to aid in the prediction of potential effects of long-term exposure to the test article.

Toxic injury to the liver can be expressed in several parameters and are routinely measured during the course of prechronic toxicity studies. These include clinical examinations; clinical chemistry of the blood, serum, and urine; absolute and relative organ weights; necropsy observations; light microscopic examination; ultrastructural examinations using transmission and scanning electron microscopy; histochemical and immunohistochemical staining; and molecular investigations for changes in gene expression. It is very important to consider all available information when evaluating the potential for a drug or chemical to induce hepatic injury. Clinical observations, changes in clinical chemistry data, and necropsy findings, in combination with the pathologist's observations when examining the liver at the light microscopic level, may lead to a proposed pathogenesis of the mechanism of injury or provide critical information to direct further investigations.

Several mechanisms of hepatic injury have been identified. While many specific mechanisms have been identified, it is often not clear which mechanism is of primary importance or exactly which mechanisms are responsible for the pathogenesis of cell injury by an individual drug or toxin. The manner in which various intracellular organelles are affected will characterize the pattern of the pathologic alterations observed. These mechanisms may involve the cell membrane, as well as intracytoplasmic organelles (Greaves, 2000; Cattley and Popp, 2002; Lee, 2004). Some of the known mechanisms are summarized in Table 1.

TABLE 1.—Hepatocellular mechanisms of cell injury.

Cytochrome P450 activation
Alcohol dehydrogenase activation
Inhibition of β-oxidation, respiration or both, leading to oxidative stress
Membrane lipid peroxidation
Protein synthesis inhibition
Cytoskeletal actin filament aggregation
Disruption of calcium homeostasis
Activation of proapoptotic receptor enzymes
Nonhepatocyte mediated injury

In the liver, there are a limited number of morphologic changes that can be discerned using conventional light microscopy. These morphologic alterations are often characterized as either "adaptive," consisting of an exaggerated normal physiologic response; "pharmacologic," consisting of an expected alteration in response to the desired action of the test article; or "adverse," consisting of morphologic alterations that are generally undesired, progressive and deleterious to the normal function of the cell(s) involved.

Often the distinction between adaptive or pharmacologic responses and adverse changes is the difference in the magnitude of a change rather than a completely different mechanism or pathway. A change which may be considered adaptive or pharmacologic in one patient may be considered adverse in a different patient. Since the toxicologic response in animals is usually observed in a dose-dependent manner, morphologic changes that may not be considered adverse at low doses may result in serious hepatotoxicity at higher doses. It is the goal of the drug development process to identify potential adverse effects of a drug and establish the dose dependency of the compound in a manner that a No-Observed-Adverse-Effect Level (NOAEL) is identified at which the compound is still pharmacologically active.

While a few of the morphologic changes observed in the liver are unique and may be considered pathognomic for a specific mode of action, many of the changes observed by the morphologic toxicologic pathologist are relatively nonspecific and often require additional study to determine the exact nature of the observed change. There are many sophisticated tools available to aid the toxicologic pathologist in the characterization of histomorphologic changes observed in routine hematoxylin and eosin stained sections. These retrospective techniques include the use of special staining procedures, electron microscopy, molecular investigations, and more recently, the use of automated pathology systems. However despite all the new techniques available, a trained toxicologic pathologist still represents the most discerning and accurate tool available for identification and interpretation of hepatic pathology. There is a great need for experienced toxicologic pathologists to interpret and record hepatic lesions consistently, within studies and between studies. In some instances, comparison of data from different pathologists is desired. In order to ensure the consistency necessary to allow meaningful comparisons of these data, it is imperative that pathologists use standardized nomenclature and diagnostic criteria when examining tissue sections.

STANDARDIZATION OF NOMENCLATURE AND DIAGNOSTIC CRITERIA

The need for standardization of nomenclature and diagnostic criteria has been widely recognized by toxicologic pathologists for years. Many efforts have been pursued to create internationally-accepted nomenclature and diagnostic criteria for proliferative lesions (hyperplasia and neoplasia) in rats and mice (Eustis et al., 1990; Goodman et al., 1994; WHO IARC, 1997; Harada et al., 1999; Deschl et al., 2001). Although similar efforts have been attempted for nonproliferative lesions, they have not resulted in a universally accepted lexicon for toxicologic pathologists to follow during the examination of tissues from animals used in the drug

development process (Detilleux, draft; Levin et al., 1999). The absence of a universally accepted lexicon has resulted in much confusion among pathologists and other scientists using large databases due to the use of different nomenclature to describe the same or similar changes observed in the liver. It would be very helpful to establish universally accepted standards for the diagnoses of changes in major target organ tissues encountered in drug discovery studies. In addition to the liver, these organs should include other tissues that are involved directly with drug metabolism, detoxification, or excretion including, but not limited to, the urogenital tract, respiratory tract, and major organs of the nervous system and immune system.

For a system of nomenclature and diagnostic criteria to be broadly applied across differing scientific disciplines, it must be uncomplicated and concise and at the same time easy to apply in a consistent and precise manner. Standardized nomenclature and diagnostic criteria must include both the topography and morphology used to describe each lesion. In addition to the morphologic diagnosis, modifiers to indicate the distribution and nature of the lesion should be routinely included as part of the final diagnosis. Fortunately, in the liver there are a limited number of well-defined terms available for each of these. Standardized nomenclature and diagnostic criteria for topographies should include the cells or other structures that are affected in the liver. This may involve hepatocytes, sinusoidal lining cells, or other nonhepatocytic cells present in the liver. The format for the topographical portion of an individual diagnosis should include the organ followed by the cell affected (e.g., Liver, Hepatocyte - ; Liver, Kupffer cell - ; etc.). The cells that should be considered when describing the topograghy are summarized in Table 2.

Morphologic evidence of adverse effects involving hepatocytes may be limited to the hepatocyte nucleus or cytoplasm, or may involve the entire cell. These changes may be distributed in a centrilobular, midzonal, periportal, nonzonal, or diffuse manner. Distribution modifiers, focal and multifocal, are not recommended for use in toxicologic pathology, since they often refer to the severity of a particular change rather than describing the distribution of a lesion. This leads to confusion when severity modifiers are also used in the same study. Nuclear changes that may be observed include karyomegaly, multinucleation, and mitotic abnormalities. Cellular alterations include degeneration, necrosis, decreased liver mass (atrophy) and fibrosis, hypertrophy, foci of cellular alteration, hyperplasia, and neoplasia. Other morphologic changes that are regarded as adverse alterations may involve the biliary system, hepatic vasculature, Kupffer cells, or stellate cells (fat storing or Ito cells). Inflammatory changes may involve a number of types of cellular infiltrates and may affect multiple cellular components of the hepatic parenchyma. Suggested nomenclature to describe morphologic alterations in the liver are presented in Table 3.

In addition to recording a topography-morphology diagnosis for each nonproliferative lesion in a study, it is also the responsibility of the pathologist to demonstrate the dose-responsive nature of each treatment-related change. In order to accomplish this, the pathologist is required to rank the lesions in order of relative severity within the study. The pathologist must categorize the magnitude of each change diagnosed in an individual animal relative to the same change that may be present in other animals in the same study. Unlike the topography-morphology diagnosis which should be consistently applied across studies by multiple pathologists, ranking of severity is only relative within an individual study and direct cross study comparisons are extremely difficult

TABLE 2.—Standardized nomenclature for cells or structures in the liver that may be affected by hepatic toxins.

Hepatocytes
Sinusoidal lining cells
Kupffer cells
Stellate (fat storing or Ito) cells
Endothelial cells
Biliary System
Canaliculi
Oval cell
Portal Tract
Hepatic artery
Portal vein
Bile duct
Lymphatic
Nerves
Connective tissue—collagen type I
Hepatic Capsule

TABLE 3.—Standardized nomenclature for nonproliferative histopathologic alterations of the liver.

Distribution Modifiers
Centrilobular
Midzonal
Periportal
Nonzonal
Diffuse
Subcapsular
Periportal
Intralobular
Morphology Descriptors
Hepatocyte (Nuclear)
Karyomegaly
Multinucleated
Increased mitoses
Hepatocyte (Cellular)
Atrophy
Glycogen accumulation/depletion
Lipid accumulation (macrovesicular, microvesicular)
Phospholipidosis
Hypertrophy
Degeneration
Necrosis (Apoptotic, oncotic)
Kupffer Cells
Hypertrophy
Pigment Accumulation
Heme pigment
Bile pigment
Ceroid pigment
Stellate (Ito) Cells
Hypertrophy
Lipid accumulation
Cystic degeneration
Sinusoid
Angiectasis
Other (nonparenchymal cells)
Inflammatory cell infiltrate
Neutrophil
Lymphoid (lymphocyte/plasma cell/macrophage)
Eosinophil
Microgranuloma
Mixed
Fibrosis

to make. Relative ranks of severity are established by the study pathologist while examining the tissues from a specific study and the range of severity of a particular finding may vary from study to study. The purpose of ranking lesions within a study is to establish a dose response, if present, and to identify the probable No-Observed-Effect Level (NOEL) or No-Observed-Adverse-Effect Level (NOAEL) for that study. The only way to compare severity ranking of a lesion across studies is to have the same individual examine all liver sections from each of the studies and rank them relative to each other.

Examples of the application of these suggested topography-morphology diagnoses are presented in Figures 1.1–1.8. These are not intended to be a complete illustrated lexicon for potential toxic-induced lesions that may be observed, but only to demonstrate the specific application of these terms to lesions that have been observed in prechronic studies conducted by the National Toxicology Program Carcinogenesis Bioassay Testing Program.

Comparison of Morphologic Observations with Data Generated by Other Disciplines in Prechronic/Chronic Toxicity Studies

In order to improve the ability of the drug discovery process to identify and characterize potential adverse effects in the liver, it is necessary to utilize all the data generated during the study. When integrating data from all aspects of a study, the data set becomes very large. Emerging data mining tools have been used and continue to be developed to identify correlates among the various data in an integrated data set that might suggest adverse effects, help characterize the mode of action or pathogenesis of the changes present, and direct further investigations. The morphologic data generated by the toxicologic pathologist are being used to help understand the enormous amount of data generated during gene expression analysis of tissue arrays produced from the liver of animals exposed to known hepatotoxins, as well as drugs and chemicals that are not considered to affect the liver. It is very important that the morphologic diagnoses in these comparative data sets be consistently recorded and be as concise and accurate as possible. The only way to achieve this goal is to apply a rigorous system of predetermined diagnostic criteria and nomenclature. Recently there have been huge advances in the fields of digital imaging and computer-assisted tissue evaluation. The use of these new advanced techniques will greatly enhance the pathologist's ability to provide the most definitive data possible.

Slide scanning optical systems are now available that capture digital images of the entire section of tissue on a slide at resolutions that can be used for visual examination as well as computerized image analysis. Automated pathology systems are currently being developed that allow the computer to perform a morphologic analysis of the tissue following predetermined algorithms designed to follow the same process used by the pathologist when examining the tissue using the light microscope (Johnson and Braughler, 2003). TissueInformatics, a division of Paradigm Genetics, has developed a software package that will separate normal liver tissue from abnormal liver tissue. In doing this, the software designers worked closely with toxicologic pathologists to determine the parameters that are examined during the pathologist's visual evaluation of a liver section to determine if it should be considered abnormal or should be considered to contain no remarkable morphologic alterations. During this development process, 94 different parameters were identified and were incorporated into the computer software program that allows the computer to use "machine vision" to separate normal from abnormal liver samples. Since the computer program is designed to consistently examine each tissue section using the exact same parameters, this should eliminate the variability in "human vision" that occurs over time with an individual pathologist and among different pathologists (Pearse et al., 2004; Willson et al., 2004).

The use of gene expression data to characterize the toxicity of hepatotoxins is another technique currently being pursued by a number of different investigators. One of the goals is to be able to correlate gene expression results with morphologic changes observed in the tissue. Currently, this involves the microscopic evaluation of formalin-fixed paraffin-embedded tissue sections stained with hematoxylin and eosin stain by a pathologist. This method is highly dependent on the training and experience of the pathologist and requires the application of a standardized system of nomenclature and diagnostic criteria in a precise and consistent manner. It is limited to the degree of visual differentiation that can be achieved by the pathologist and may be affected by diagnostic drift or microscope fatigue. Recently, the use of automated pathology systems to provide the morphologic assessment of the tissue has been investigated to supplement the visual examination by a pathologist (Kriete et al., 2003; Kriete and Boyce, 2003; Young et al., 2003). By using automated tissue scanning microscopes and computer programs designed to identify abnormal tissue morphology, the process of correlating gene expression data and morphologic data may be automated. This would lead to rapid and consistent results and avoid variables associated with human visual examination. It is important to remember, however, that the computerized approach only makes mathematical comparisons, and the pathologist must evaluate the data and determine the biologic significance and the importance of any correlations that result from this automated approach.

The importance of the use of a standardized system of nomenclature and criteria for recording hepatic changes associated with prechronic and chronic toxicity studies cannot be overemphasized. Whether the study results are being used for experimental research purposes to study mechanisms of toxicity or for regulatory purposes to establish safety levels for human exposure, the pathologist must be able to communicate the findings in a clear and concise manner consistent within a study and across studies so that comparisons of relative toxicity can be accomplished. Not only is there a need for a standardized system of nomenclature and diagnostic criteria for the diagnoses of tissue changes associated with organ toxicity, but pathologists must be aware that the consistent application of the criteria is critical to the scientific and regulatory communities. By achieving these goals, it will be possible for all involved in a multidisciplinary approach to experimental and regulatory toxicology to communicate with each other in a

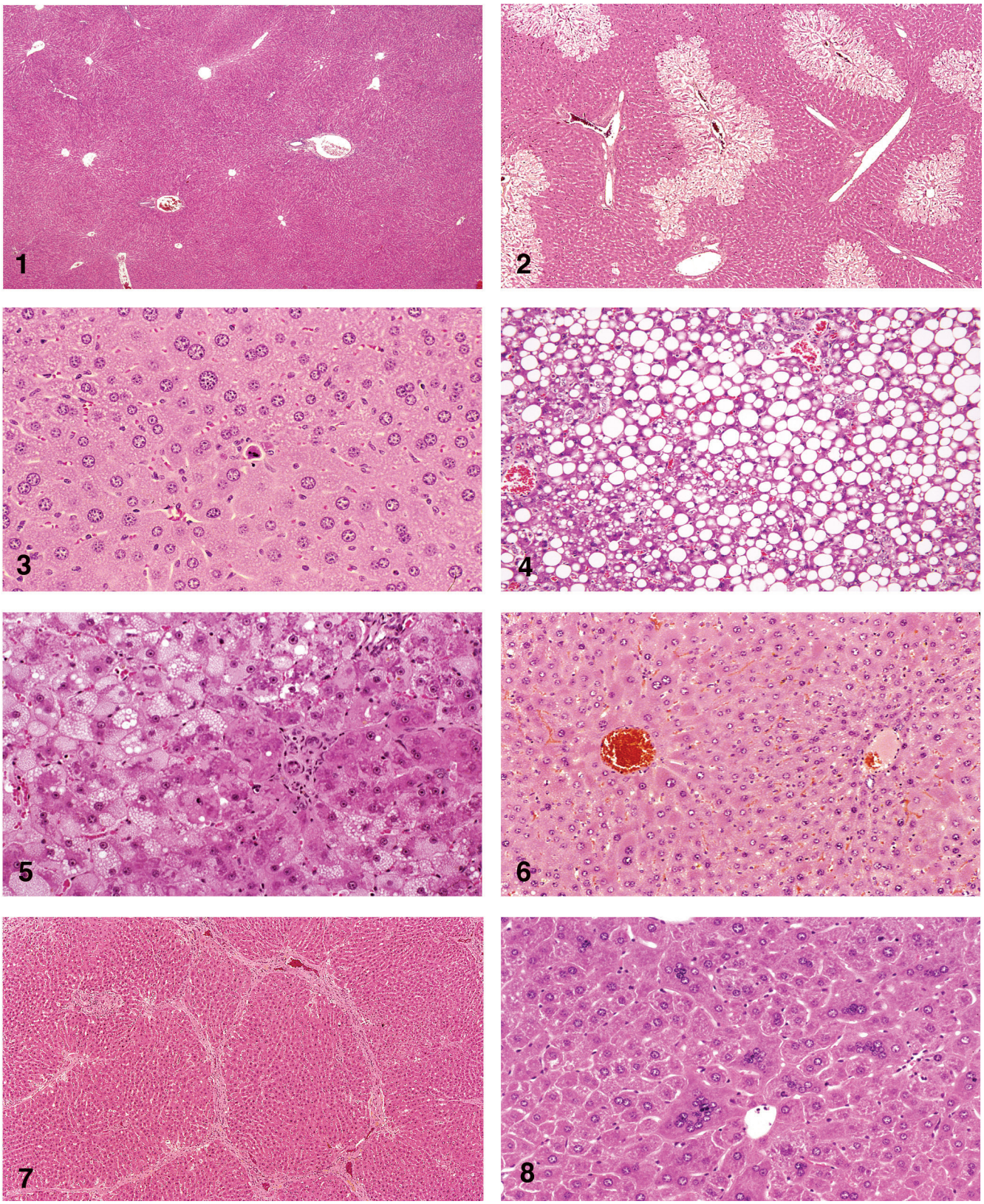

FIGURE 1.—Diagnoses with magnification at time of image capture. (1) Normal control (A445555). H&E. ×4.0; (2) Centrilobular oncotic necrosis (A14851). H&E. ×13.2; (3) Nonzonal apoptotic necrosis (E10133). H&E. ×80; (4) Nonzonal macrovesicular lipid accumulation (A46017). H&E. ×20; (5)Nonzonal microvesicular lipid accumulation (A42564) H&E. ×50; (6) Centrilobular hypertrophy (A19486). H&E. ×40; (7) Fibrosis, periportal (A30212). H&E. ×13.2; (8) Hepatocyte, multinucleated (A08712). H&E. ×50.

meaningful manner leading to a better understanding of the entire process.

REFERENCES

Cattley, R. C., and Popp, J. A. (2002). Liver. In Handbook of Toxicologic Pathology (W. M. Haschek, C. G. Rousseaux, and M. A. Wallig, eds.), 2nd ed., Vol. 2, pp. 187–222. Academic Press, San Diego.

Deschl, U., Cattley, R. C., Harada, T., Küttler, K., Hailey, J.R., and Hartig, F. (2001). Liver, gallbladder and exocrine pancreas. In: International Classification of Rodent Tumours: The Mouse (U. Mohr, ed.), pp. 59–86. WHO International Agency for Research on Cancer, Springer, Berlin.

Detilleux, P. G., Gruebbel, M. M., Botts, S., Cattley, R. C., Cheville, N. F., and Goodman, D. G. (Final draft). Non-proliferative changes of the liver, exocrine pancreas, and salivary gland of the rat. In Guides for Toxicologic Pathology. STP/ARP/AFIP, Washington, DC.

Eustis, S. L., Boorman, G. A., Harada, T., and Popp, J. A. (1990). Liver. In: Pathology of the Fischer Rat (G. A. Boorman, S. L. Eustis, M. R. Elwell, C. A. Montgomery, Jr., and W. F. Mackenzie, eds.), pp. 71–92. Academic Press, San Diego.

Food and Drug Administration, U.S. Department of Health and Human Services, (March 2004). "Challenge and Opportunity on the Critical Path to New Medical Technologies."

Goodman, D. G., Maronpot, R. R., Newberne, P. M., Popp, J. A., and Squire, R. A. (1994). Proliferative and selected other lesions of the liver in rats. GI-5. In Guides for Toxicologic Pathology. STP/ARP/AFIP, Washington, DC.

Greaves, P. (2000). Digestive system 2, liver, bile ducts, biliary system, exocrine pancreas. In Histopathology of Preclinical Toxicity Studies, Interpretation and Relevance in Drug Safety Evaluation, 2nd ed. pp. 432–71.

Harada, T., Enomoto, A., Boorman, G. A., and Maronpot, R. R. (1999). Liver and gallbladder. In Pathology of the Mouse (R. R. Maronpot, ed.) pp. 119–71. Cache River Press, Vienna, IL.

Johnson, P. C., and Braughler, M. (2003). Automated pathology software in toxicology and drug safety. *Curr Drug Disc* 23–28.

Kriete, A., Anderson, M. K., Love, B., Freund, J., Caffrey, J. J., Young, M. B., Sendra, T. J., Magnuson, S. R., and Braughler, J. M. (2003). Combined histomorphometric and gene-expression profiling applied to toxicology. *GenBiol* **4**(5), R32.

Kriete, A., and Boyce, K. (2003). Advanced tissue analysis using a combined histomorphometric and gene expression profiling method. *SPIE Proc* **4958**, 137–43.

Lee, W. M. (2004). Drug-induced hepatotoxicity. *New Engl J Med* **349** 474–85.

Levin, S., Bucci, T. J., Cohen, S. M., Fix, A. S., Hardisty, J. F., LeGrand, E. K., Maronpot, R. R., and Trump, B. F. (1999). The nomenclature of cell death: recommendations of an ad hoc committee of the Society of Toxicologic Pathologists. *Toxicol Pathol* **27**(4), 484–90.

Pearse, G., Joron, T., Willson, G., and Hardisty, J. (2004). Use of automated pathology to confirm results of pathological examination of NTP studies. Poster presented at the Society of Toxicologic Pathology 23rd Annual Meeting, Salt Lake City, Utah, June 13–17, 2004.

Ward, J. M., Hardisty, J. F., Hailey, J. R., and Street, C. S. (1995). Peer review in toxicologic pathology. *Toxicol Pathol* **23**(2).

WHO International Agency for Research on Cancer (1997). International classification of rodent tumours, Part I. The rat. Digestive System (U. Mohr, ed.), pp. 65–83. IARC Scientific Publications IARC, Lyon.

Willson, G., Joron, T., Pearse, G., and Hardisty, J. (2004). Comparison of automated pathology with conventional histopathology of liver step sections in an NTP subchronic bioassay. Poster presented at the Society of Toxicologic Pathology 23rd Annual Meeting, Salt Lake City, Utah, June 13–17, 2004.

Young, M. B., DiSilvestro, M. R., Sendera, T. J., Freund, J., Kriete, A., and Magnuson, S. R. (2003). Analysis of gene expression in carbon tetrachloride-treated rat livers using a novel bioarray technology. *Pharmacogen J* **3**(1), 41–52.