This project was funded in part by the Dean's Office, College of Veterinary Medicine, Oregon State University, and the National Animal Disease Center, Agricultural Research Service, USDA.

References

1. Bigler WJ, Jenkins JH, Cumbie PM, et al.: 1975, Wildlife and environmental health: raccoons as indicators of zoonoses and pollutants in the southeastern United States. J Am Vet Med Assoc 168:592–597.
2. Chandler FW, Kalpan W, Ajello L: 1980, Adiaspiromycosis. *In:* Color atlas and text of the histopathology of mycotic diseases, pp. 30–33. Year Book Medical Publishers, Chicago, IL.
3. Chandler FW, Watts JC: 1987. Adiaspiromycosis. *In:* Pathologic diagnosis of fungal infections, pp. 35–41. ASCP Press, Chicago, IL.
4. Dubey JP, Hamir AN, Hanlon CA, et al.: 1990, Fatal necrotizing encephalitis in a raccoon associated with a *Sarcocystis*-like protozoon. J Vet Diagn Invest 2:345–347.
5. Emmons CW, Bindford CH, Utz JP, Kwon-Chung KJ: 1977, Medical mycology, 3rd ed. Lea and Febiger, Philadelphia, PA.
6. Hamir AN: 1998, Capillariasis of the anal sacs of raccoons (*Procyon lotor*), and a possible association with anal sac impaction. J Vet Diagn Invest 10:371–373.
7. Hamir AN, Fischer KA: 1999, Neuronal vacuolations in raccoons from Oregon. J Vet Diagn Invest 11:303–307.
8. Hanlon CL, Hayes DE, Hamir AN, et al.: 1989, Proposed field evaluation of a rabies recombinant vaccine for raccoons (*Procyon lotor*). Site selection, target species characteristics, and placebo baiting trials. J Wild Dis 25:555–567.
9. Jellison WL: 1969, Adiaspiromycosis. Mountain Press, Missoula, MT.
10. Jones CT, Hunt RD, King NW: 1997, Adiaspiromycosis (haplomycosis) *In:* Veterinary pathology, 6th ed., pp. 512–513. Williams and Wilkins, Baltimore, MD.
11. Koller LD, Helfer DH: 1978, Adiaspiromycosis in the lungs of a goat. J Am Vet Med Assoc 173:80–81.
12. Koller LD, Patton NM, Whitsett DK: 1976, Adiaspiromycosis in the lungs of a dog. J Am Vet Med Assoc 169:1316–1317.
13. Rippon JW: 1988, Adiaspiromycosis. *In:* Medical mycology, 3rd ed., pp. 718–721. WB Saunders, Philadelphia, PA.
14. Snyder DE, Sanderson GC, Toivio-Kinnucan M, Biagburn BL: 1990, *Sarcocystis kirkpatricki* n. sp. (Apicomplexa; Sarcocystidae) in muscles of raccoons (*Procyon lotor*) from Illinois. J Parasitol 76:495–500.

J Vet Diagn Invest 11:567–569 (1999)

Enhanced detection of *Cryptosporidium parvum* in the acid-fast stain

Christine Kodric Nielsen, Lucy Ann Ward

Cryptosporidiosis is an important zoonotic disease concern requiring safe and specific methods of diagnosis. *Cryptosporidium parvum* infections are highly prevalent among young calves worldwide, especially in those around 2 weeks of age.[8] In a US study, *Cryptosporidium* was found in 32% of 860 bovine enteritis cases and, in 16% of the cases, was the only pathogen present.[13] *Cryptosporidium parvum* may also be found in calves with normal formed stool.[15] Clinical disease ranges from asymptomatic to profuse watery diarrhea. Although *C. parvum* infections are generally self-limiting, infections in the very young or immunocompromised host are often debilitating and sometimes fatal. Fecal–oral contamination is the most common route of transmission. There are no effective chemotherapeutic agents available to treat cryptosporidiosis.

The scientific literature is replete with diagnostic procedures for the detection of *Cryptosporidium* in feces. DNA amplification by the polymerase chain reaction (PCR) is probably the most sensitive assay, detecting 100–1,000 oocysts per gram of feces.[10] However, this procedure is time consuming, and the necessary reagents are costly. Immunofluorescent antibody staining (IFA) is used more frequently than PCR, but it also is relatively costly and displays low sensitivity, requiring as many as 50,000–500,000 oocysts per gram of feces for samples to give a positive reaction.[16] Negative staining and various modified Ziehl-Neelsen (ZN) acid-fast (AF) methods have been the topic of many studies.[3,9,14] The ZN AF staining method, first used to detect *Cryptosporidium* oocysts in feces in 1981,[11] is probably the most widely used method because of its simplicity and low cost,[7] although it too displays low sensitivity in feces (requiring 500,000 oocysts/g).[16] Several fluorescent stains have also been employed for the detection of *Cryptosporidium* that exhibit potentially higher sensitivities (lower signal to noise ratio) than the AF stain. However, the AF stain allows for identification of other AF pathogens within a sample (i.e., *Cyclospora*), resulting in an advantage over both IFA and flourescent stain detection methods.

Many coccidian parasites, such as *Isospora*, *Eimeria*, and *Cyclospora*, exhibit autofluorescence when unstained wet-mount preparations are viewed under ultraviolet (UV) light. Examination of unstained fecal smears under UV light (365 nm) is more sensitive than AF staining for the diagnosis and confirmation of *Isospora* and *Cyclospora*.[1,6] *Cryptosporidium* does not exhibit autofluorescence in unstained smears. However, when AF stained and examined under UV light with a 540–560-nm (rhodamine) filter, *C. parvum* oocysts will fluoresce brightly.

Twenty-five previously screened fecal samples deemed

From the Food Animal Health Research Program, Department of Veterinary Preventive Medicine, Ohio Agricultural Research and Development Center, Ohio State University, 1680 Madison Avenue, Wooster, OH 44691.

Received for publication December 14, 1998.

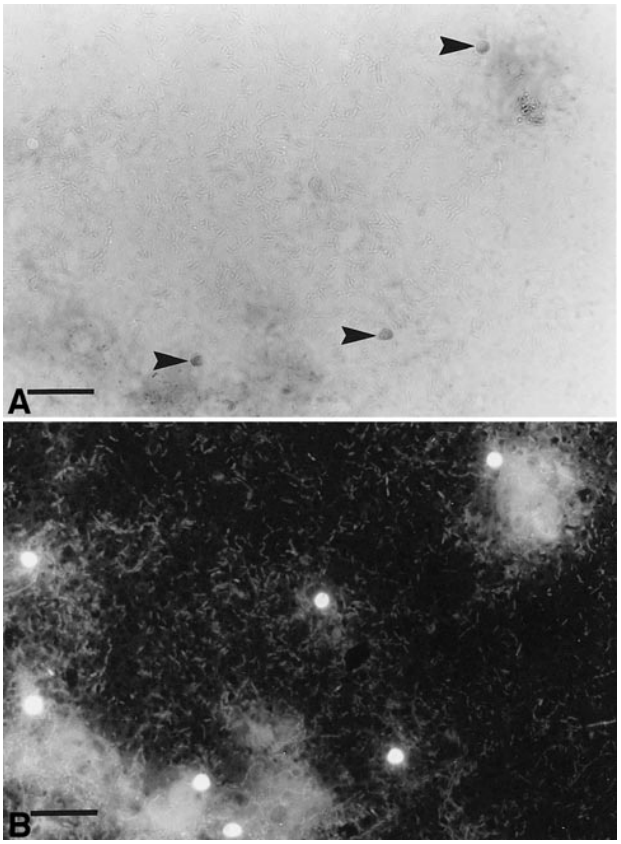

Figure 1. *Cryptosporidium parvum* oocysts Acid-fast stain. Bar = 30 μm. **A**. Brightfield microscopy. Three acid-fast oocysts (arrowheads) are visible. Note the presence of ghosts. **B**. UV light with a 540-560nm filter. Seven oocysts are visible in the same field.

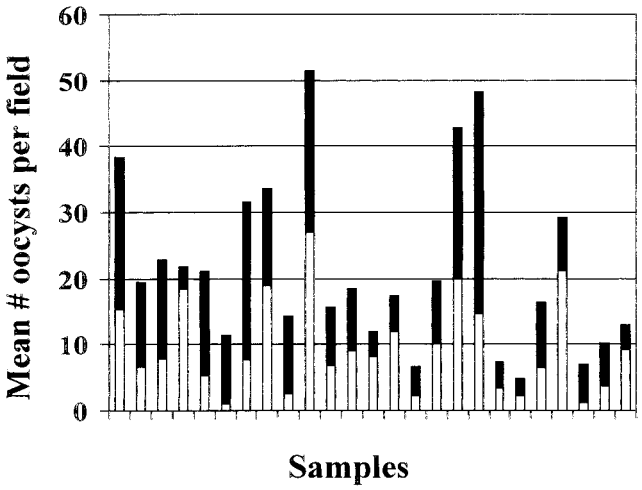

Figure 2. The mean number of oocysts in each sample under brightfield (□) and UV (■) conditions. The number of oocysts observed in 5 randomly selected fields under 400× magnification was counted, and the numbers wer averaged to obtain the mean number per slide. The mean under UV light was significantly higher than the mean under brightfield conditions ($P < 0.01$).

positive by AF staining under brightfield light were further evaluated. Samples were prepared by smearing feces over an approximately 2.5- × 3.0-cm area of a clean glass slide, air drying, and fixing in 100% methanol for 10 minutes. Fixed slides were air dried and then stained for 3 minutes in cold carbol fuchsin,[a] rinsed in tap water, decolorized (3 ml concentrated HCl, 97 ml 100% ethanol, and 100 ml distilled water) for 30 seconds, rinsed in tap water, counterstained for 1 minute with brilliant green,[a] rinsed in tap water, air dried, and coverslipped with synthetic mounting medium.[b] Stained slides were examined by light microscopy[c] at 400× magnification under brightfield and UV (540–560 nm) illumination. The number of visible oocysts in 5 random fields on each slide were counted and averaged. The difference between the average number of oocysts enumerated under brightfield light microscopy versus the average number of oocysts enumerated under UV light microscopy was determined by a 2-tailed *t*-test, and significance was assessed at $P < 0.01$.

Under brightfield light, *C. parvum* oocysts stained varying degrees of red (AF staining) on a blue-green background (Fig. 1a). Stained oocysts were round and 4–6 μm (ocular microtomy) in diameter and occasionally contained dark internal structures (apical complexes, sporozoites). Variable numbers of ''ghost'' oocysts of the same shape and size as typical stained oocysts but lacking color and internal structures were also observed. Under UV light (540–560 nm), both stained and ghost oocysts fluoresced a bright red to white against a deep red to black background, with most oocysts showing some evidence of internal structure (Fig. 1b). Oocysts were readily differentiated from yeast cells by their staining characteristics. Yeast cells were typically AF negative, appearing pale green to gold under brightfield light and nonfluorescent under UV light. Pollen, spores, and other vegetative cells or debris would occasionally fluoresce under the UV light but were distinguishable by their size, geometric shape, and lack of internal structure.

The mean number of oocysts enumerated under UV light was significantly higher than the number found under brightfield light, with 1.2–11.4 times more oocysts observable under UV light (Fig. 2). Although the number of oocysts enumerated under brightfield light was positively correlated with the number enumerated under UV light ($R = 0.83$), the average number obtained under UV light was always greater than that obtained under brightfield light (slope > 1, Fig. 3).

Other investigators have reported that as few as 2–25% of the oocysts present in feces may be detected by AF staining.[5,7,12] The remaining 75–98% of oocysts do not display AF characteristics and appear as pale or unstained ghosts. Ghost oocysts are continually shed during infections[3] and increase in numbers during resolution of cryptosporidiosis.[2] The fact that ghosts escape normal centrifugation and do not float or sediment as expected combined with their AF negative characteristics under brightfield light microscopy give rise to false-negative results or inaccurate assessment of the severity of infection. Although ghosts have been described as empty cyst walls,[2,3] the presence of discernable internal structures within the ghosts under UV light examination in this study suggests otherwise.

The AF staining principle is not clearly understood. The

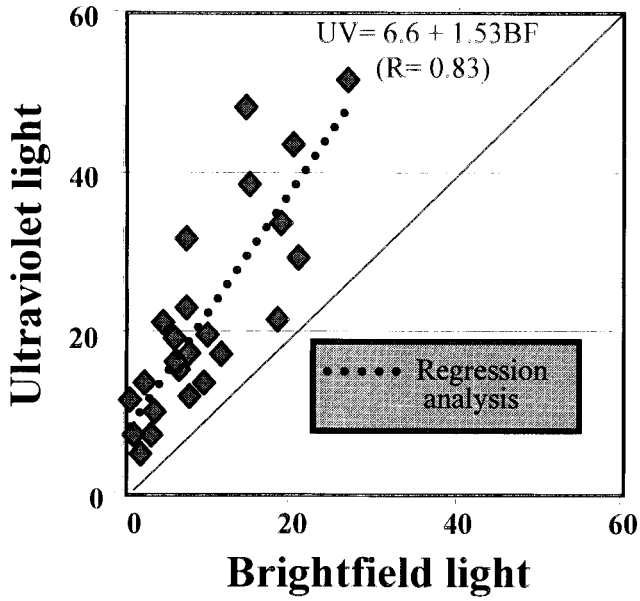

Figure 3. Correlation between the mean number of oocysts observed under brightfield and under UV conditions. The slope from linear regression analysis indicates that more oocysts were always observed under UV light than under brightfield conditions.

lipid content of organisms is suspected to be directly related to their acid-fastness. Carbol fuchsin is more soluble in lipids than in acid-alcohol and thus resists decolorization.[4] Less than half (42%) of the oocysts displayed AF fast properties under brightfield light microscopy in the present study. However, when the AF stain was combined with epifluorescence, all oocysts, including ghosts, were easily visualized. The presence of ghost oocysts probably explains in part why the reported sensitivity of the IFA is greater than that of the AF stain for detecting *C. parvum* oocysts in feces.[16] In an earlier study, the threshold of detection was established at 10^4 oocysts/g of feces for a commercial IFA product[d] and 10^5 oocysts/g for the AF stain as described here under brightfield light. However, when the AF stain was combined with epifluorescence, the sensitivity of the AF stain increased 10-fold, to 10^4 oocysts/g (data not shown).

In this laboratory, the AF stain has been used with epifluorescence to evaluate over 1,000 clinical and experimental fecal specimens collected from young calves and pigs. This method greatly improves the ease of detecting *Cryptosporidium* oocysts in fecal smears and enhances the sensitivity of the AF stain to levels comparable with IFA detection. Other AF parasites, such as *Cyclospora,* have also been visualized by this method. Although *Cyclospora* will autofluoresce with a 365-nm excitation filter, a separate wet mount must be made. An advantage to this method is that only one slide preparation for the detection of AF parasites is needed. Thus, this procedure offers a rapid inexpensive method for detecting *Cryptosporidium* and other AF parasites, such as *Cyclospora,* in fecal specimens.

Acknowledgements. We are grateful to Dr. Doug Hodgins for assistance with the statistical analysis and to Amanda Wolf and Emily Fanton for technical assistance. This work was supported in part by grants from the Ohio State University and the US Environmental Protection Agency (R826138).

Sources and manufacturers

a. Volu-Sol, Salt Lake City, UT.
b. Cytoseal 60, Stephens Scientific, Riverdale, NJ.
c. Carl Zeiss Jena GmbH, Jena, Germany.
d. MERIFLOUR™ Meridian Diagnostics, Cincinnati, OH.

References

1. Berlin OGW, Conteas CN, Sowerby TM: 1996, Detection of *Isospora* in the stools of AIDS patients using a new rapid autofluorescence technique. AIDS 10:442–443.
2. Bogaerts J, Lepage P, Rouvroy D, Vandepitte J: 1984, *Cryptosporidium* spp., a frequent cause of diarrhea in central Africa. J Clin Microbiol 20:874–876.
3. Bronsdon MA: 1984, Rapid dimethyl sulfoxide-modified acid-fast stain of *Cryptosporidium* oocysts in stool specimens. J Clin Microbiol 19:952–953.
4. Carson FL: 1997, Microorganisms. *In:* Histotechnology: a self-instructional text, 2nd ed., pp. 180–182. American Society of Clinical Pathologists Press, Chicago, IL.
5. Cozon G, Cannella D, Biron F, et al.: 1992. *Cryptosporidium parvum* sporozoite staining by propidium iodide. Int J Parasitol 22:385–389.
6. Dytrych JK, Cooke RPD: 1995, Autofluorescence of *Cyclospora*. B J Biomed Sci 52:76.
7. Entrala E, Rueda-Rubio M, Janseen D, Mascaro C: 1995, Influence of hydrogen peroxide on acid-fast staining of *Cryptosporidium parvum* oocysts. Int J Parasitol 25:1473–1477.
8. Fayer R, Speer CA, Dubey JP: 1997, The general biology of *Cryptosporidium. In: Cryptosporidium* and cryptosporidiosis, ed. Fayer R, p. 19. CRC Press, Boca Raton, FL.
9. Garcia LS, Bruckner DA, Brewer TC, Shimizu RY: 1983, Techniques for the recovery and identification of *Cryptosporidium* oocysts from stool specimens. J Clin Microbiol 18:185–190.
10. Gobet P, Buisson JC, Vagner O, et al.: 1997, Detection of *Cryptosporidium parvum* DNA in formed human feces by a sensitive PCR-based assay including uracil-*N*-glycosylase inactivation. J Clin Microbiol 35:254–256.
11. Henriksen SA, Pohlenz JF: 1981, Staining of cryptosporidia by a modified Ziehl-Neelsen technique. Acta Vet Scand 22:594–596.
12. Miller RA, Holmberg RE, Clausen CR: 1983, Life-threatening diarrhea caused by *Cryptosporidium* in a child undergoing therapy for acute lymphocytic leukemia. J Pediatr 103:256–259.
13. Moore DA, Zeman DH: 1991, Cryptosporidiosis in neonatal calves: 277 cases (1986–1987). J Am Vet Med Assoc 198:1969–1971.
14. Pohjola S: 1984, Negative staining method with nigrosin for the detection of cryptosporidial oocysts: a comparative study. Res Vet Sci 36:217–219.
15. Ridley RK, Olsen RM: 1991, Rapid diagnosis of bovine cryptosporidiosis with a modified commercial acid-fast staining procedure. J Vet Diagn Invest 3:182–183.
16. Weber R, Bryan RT, Bishop HS, et al.: 1991, Threshold of detection of *Cryptosporidium* oocysts in human stool specimens: evidence for low sensitivity of current diagnostic methods. J Clin Microbiol 29:1323–1327.